

# Evaluation of posterior femoral condyle depth as an anatomical risk factor for anterior cruciate ligament injury among Egyptian population: a case–control study

Eltregy Sherif

Department of Orthopedic, Benha University, Benha, Egypt

Correspondence to Sherif Eltregy, MD, Department of Orthopedic, Benha University Hospitals, Fareed Nada Street, Benha, Qalyobeya, Egypt.  
e-mail: shareeftraigy07@gmail.com

**Received:** ?????

**Revised:** 30 November 2

**Accepted:** ?????

**Published:** xx xx 2020

**The Egyptian Orthopaedic Journal** 2021, ??:??–??

## Background

The purpose of this study was to investigate the influence of posterior femoral condylar depth on risk of sustaining anterior cruciate ligament (ACL) injury among the Egyptian population.

## Patients and methods

A total of 400 patients (200 ACL ruptured and 200 ACL intact) were included. Morphometric parameters were measured on knee lateral radiographs, with overlapping of the femoral condyles. Radiographic measurements included the posterior femoral condyle offset (PCO) and ratio.

## Results

The PCO and ratio showed significant differences between both groups. The receiver-operating characteristic curve revealed that the PCO cutoff value of more than 67.8 was associated with increased ACL injury with 76% sensitivity and 74% specificity.

## Conclusions

The data from our study demonstrated that an increase in posterior femoral condyle ratio was associated with an increased prevalence of ACL injuries in Egyptian population. However, further research is needed to determine the distal femur morphology in the Egyptian population and its effect on the risk of primary and secondary ACL injury.

## Level of evidence

Level III, case–control study.

## Keywords:

anatomical risk factor, anterior cruciate ligament injury, posterior femoral condylar depth, posterior femoral condylar offset and ratio

Egypt Orthop J ??:??–??

© 2021 The Egyptian Orthopaedic Journal  
1110-1148

## Introduction

Injuries to the anterior cruciate ligament (ACL) are devastating with important social–economic implications [1–3]. Identification of the risk factors that can predispose the individual to a potential higher risk of sustaining an ACL injury is of paramount importance [1,4]. Several environmental, hormonal, neuromuscular, anatomical, and biomechanical risk factors have been investigated [5–7]. Few recent studies have focused on the posterior femoral condylar depth as a risk for ACL injury [1,8]. Pfeiffer *et al.*'s [8] work was among the earliest reports on the relevance of such variant being measured in radiographs. They emphasized the importance of screening measures to identify susceptible population. The purpose of this study was to investigate the influence of posterior femoral condylar depth on risk of sustaining ACL injury among the Egyptian population using plain radiographs. Using MRI for the same purpose can be more accurate, however being much more expensive, operator dependent, and having long

waiting lists of patients make MRI a less desirable option for screening and of less availability at certain places in Egypt, where a good quality MRI can be difficult to obtain.

## Patients and methods

Following University Review Board approval (Research Ethics Committee certificate 000059/6.6.17) and written informed consent was collected from all participants, 200 prospectively studied consecutive patients (who had complete ACL tear who were planned to have an arthroscopic reconstruction at our university hospital during the period from January 2017 to April 2019) were included in this study as a case group. Another 200 cases that would go for knee arthroscopy (meniscal, osteochondral, or synovial disorders) without

This is an open access journal, and articles are distributed under the terms of the Creative Commons Attribution-NonCommercial-ShareAlike 4.0 License, which allows others to remix, tweak, and build upon the work non-commercially, as long as appropriate credit is given and the new creations are licensed under the identical terms.

any knee ligament injury or instability were also screened as a control group. No age limit was predetermined for patients included in this study.

Exclusion criteria comprised any case with moderate to severe knee arthritis, previous distal femur fractures, previous distal femur osteotomies, and patients with generalized ligament laxity and femoral dysplasia.

All cases included were carefully examined and tested for ACL injury and joint stability. A high-quality nonweight-bearing standard lateral radiograph with less than 6 mm of overlap between the posterior halves of the medial and lateral femoral condyles was obtained for all cases. A true horizontal beam lateral projection was defined to have superimposition of the medial and lateral condyles of the distal femur, an open patellofemoral joint space, and slight superimposition of the fibular head with the tibia. An overlap of less than 6 mm was considered to be the upper limit of accepted rotation.

To obtain such view the patient should be lying supine on the table with the targeted knee flexed slightly (30–60°), while the detector should be placed against the medial side of the knee running parallel to the leg, held by the patient or sandbags, and the long axis of the femur is to be running perpendicular to the beam.

Two radiography technicians were instructed of the planned measurements and the previously mentioned details of patients' position and radiograph criteria

were thoroughly revised with them together with the technical advice to correct a malrotated projection.

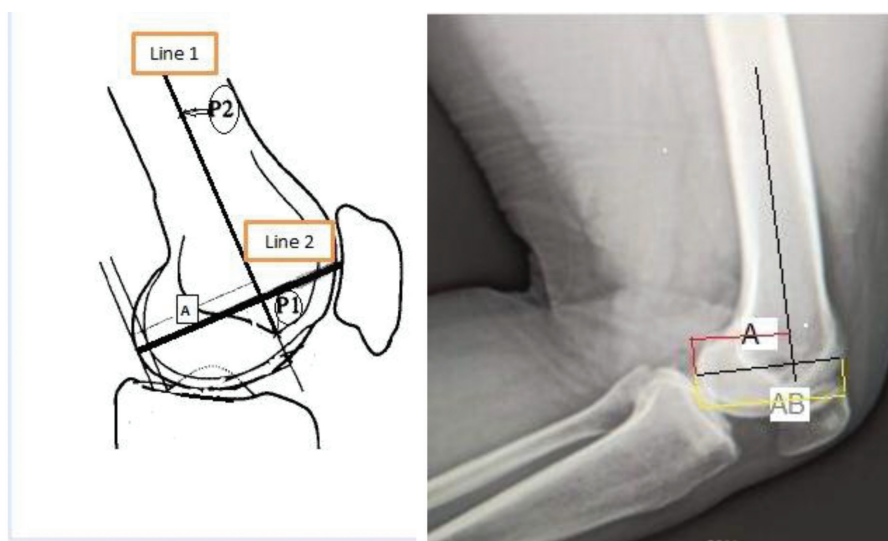
#### Measurement of posterior femoral condyle offset and ratio

The long axis of the distal femoral shaft (line 1) was drawn from the most distal point of the anterior angle of Blumensaat's line (P1) to the center of the femoral shaft 10 cm above the joint line (P2) (Fig. 1). The axis of the femoral condyle (line 2) was then determined by drawing a line between the most posterior and anterior points of the lateral femoral condyle. The posterior femoral condyle offset (PCO) is the outcome of the distance from the intersection of the previous two lines to the most posterior point of the femoral condyle (A) divided by the total anteroposterior length of the condyle (AB) (i.e.  $PCO=A/AB$ ). The posterior femoral condyle offset ratio (PCOR) is the outcome of the posterior condyle offset multiplied by 100%. (i.e.  $PCOR=A/AB\%$ ). Radiographic measurements for all cases were performed by two blinded authors and the mean measurement was used.

#### Data management and analysis

The collected data was statistically analyzed using IBM SPSS Statistics, version 22.0 (IBM Corp., Armonk, New York, USA). Data was presented and suitable analysis was done according to the type of data obtained for each parameter. Significant and highly significant correlations were considered when *P* value less than 0.05 and less than 0.01, respectively.

Figure 1



Measurement of posterior femoral condyle offset. (a) Diagram: line 1 (the long axis of the distal femoral shaft) was drawn from P1 (the most distal point of the anterior angle of Blumensaat's line) to P2 (the center of the femoral shaft 10 cm above the joint line). Line 2 (the axis of the femoral condyle) was drawn between the most posterior and anterior points of the lateral femoral condyle. 'A' is the distance from the intersection of the previous two lines to the most posterior point of the femoral condyle. (b) Radiograph: 'AB' is the total anteroposterior length of the condyle. The posterior femoral condyle offset (PCO) is the outcome of 'A': divided by 'AB' (i.e.  $PCO=A/AB$ ).

Receiver-operating characteristic (ROC) analysis was performed to determine the optimal PCO cutoff value for detecting increased risk for ACL injury. A prestudy sample size calculation revealed that a number of 112 patients in each group is needed to reach a power of 0.95.

## Results

Regarding the demographic data of patients, there was a significant difference in age ( $P=0.003$ ) between the control group and the case group, while there were insignificant differences in sex or BMI ( $P=0.14$ ,  $0.6$ , respectively) (Table 1).

In this study, there was a significant difference in posterior femoral condyle measurements (A distance) and total lateral femoral condyle measurements (AB distance) between both groups ( $P<0.001$ ) (Table 2). The PCO and PCOR showed significant differences between both groups. The ROC curve (Table 3) revealed that a PCO cutoff value of more than 67.8 was associated with increased ACL injury with 76% sensitivity and 74% specificity.

## Discussion

In the field of orthopedic surgery and sports injuries, the investigation and identification of risk factors for ACL injury is of paramount importance [1]. Increased PCO and PCOR is one of the important anatomical

risk factors. This factor could assist in identifying individuals susceptible to ACL injury, who may benefit from targeted ACL injury-prevention counseling and interventions. If a high risk of injury is confirmed, health and sports participation counseling and neuromuscular prevention programs should be strongly recommended [9]. Moreover, it could guide treatment decisions in patients undergoing ACL reconstruction that may benefit from additional surgical procedures such as extra-articular tenodesis or anterolateral ligament reconstruction [9]. It was reported in the literature that these additional surgical procedures reduce residual knee laxity and provide greater rotational stability to the knee [10–13]. Furthermore, in revision and re-revision of ACL reconstruction, the assessment of bony risk factors may yield an important role in the preoperative planning as they have been suggested as a potential cause of revision failure [14,15].

The changes in distal femoral osseous morphology may be associated with an elevated risk of ACL injury for several reasons related to the impact on knee kinematics. Moreover, it was hypothesized that altered tibiofemoral interactions caused by an increased posterior femoral condylar depth may contribute to the altered gait and loading mechanics that are shown to predict a greater risk of ACL injuries [8].

The study conducted by Pfeiffer *et al.* [8] was one of the earliest studies that identify the influence of posterior femoral condylar depth on the risk of ACL injury. They studied 175 patients and divided them into four groups (control, primary ACL injury, failed ACL reconstruction, and contralateral ACL injury groups). Patients in the first three groups had a significantly higher cam ratio compared with the control group ( $P<0.008$ ). ROC curve analysis demonstrated that a cam ratio of more than or equal to 63% was associated with an increased risk for ACL injury with a sensitivity of 83% and a specificity of 71%. They hypothesized that an increased posterior femoral condylar depth may predispose to ACL injury due to altered tibiofemoral mechanics or a relative laxity of

**Table 1 Patients' demographics in the two groups**

	Control group	Case group	Total	P value
Age				
Mean±SD	39.23±9.44	34.23±8.23	36.73±7.78	0.003
Range	25–40	25–44	25–44	
Sex [n (%)]				
Male	156 (78)	172 (86)	328 (82)	0.14
Female	44 (22)	28 (14)	72 (18)	
BMI				
Mean±SD	28.33±2.44	28.34±2.56	28.33±2.55	0.6
Range	26.22–29	26.77–29.5	26.22–29.5	

**Table 2 Measurements in the two groups**

	Control group	Case group	Total	P value
A distance	141.43	85.27	113.35 ±10.85	<0.001
AB distance	210.27	118.97	164.62 ±15.23	<0.001
PCO	0.66±0.04	0.7±0.05	0.68±0.03	<0.001
PCOR	65.65±2.56	69.88 ±3.66	67.76±3.66	<0.001

PCO, posterior femoral condyle offset; PCOR, posterior femoral condyle offset ratio.

**Table 3 Receiver-operating characteristic curve**

AUC	95% confidence interval	Significance	Cutoff value	Sensitivity	Specificity
0.825	0.765 to 0.875	<0.001	76%	76%	74%

AUC, area under the curve.



lateral and anterolateral knee structures in certain positions.

To the authors' knowledge, our study is the first one that investigated the posterior femoral condyle depth as a risk factor for ACL injury among the Egyptian population. Our study collected data from 200 patients who had ACL injury and compared the measurements with another 200 patients without any knee ligamentous injury to detect the ROC curve analysis and demonstrate the sensitivity and specificity of PCO as a novel anatomical factor for ACL injury. The ACL injury group had significantly higher posterior femoral condyle ratio compared with the control group and a cutoff value of 67.8% had a corresponding sensitivity of 76% and specificity of 74% for identifying ACL injury.

The difference in cutoff value between this study and the study of Pfeiffer *et al.* [8] may be due to race changes or the relative changes in ACL demographic distribution in our country. Decreased contribution of Egyptian females in contact sports may be one of the reasons for decreased incidence of ACL injuries in females in Egypt. Moreover, the exclusion of nearly one-third of eligible patients in the Pfeiffer *et al.* [8] study because of poor-quality imaging could introduce bias.

MRI, rather than lateral knee radiographs, could be a more precise technique to independently measure posterior condylar depth for both medial and lateral femoral condyles. There were few published studies that had already demonstrated techniques for making such measurements with the use of MRI [16,17]. The study by Voleti *et al.* [16] demonstrated that radiographs underestimate posterior condylar depth measurements when compared with MRI [16]. The use of MRI could allow to separately quantify posterior condylar depths of both femoral condyles, to independently assess their influence on the risk of ACL injury, and to reduce measurement imprecision and patient exclusion because of malrotated radiographs. However, we believe that plain radiographs, when excuted properly, can be a more applicable and much less expensive and less time-consuming method of screening that can dodge the long waiting lists of patients waiting for MRI, especially that an MRI with good quality of technical execution and reporting can be difficult to obtain in many regions in Egypt. False results due to malrotation of radiography views can be kept to a minimum by accepting no overlap of more than 5 mm between condyles, as defined by Pfeiffer *et al.* [8], who performed a pilot interobserver reliability

analysis to determine the upper limits of acceptable rotation of radiographs through an intraclass correlation coefficient analysis with a threshold of more than 0.77 for overlap of 0–6 mm. The depth of the distal femoral condyles may be one of the important intrinsic risk factors for primary ACL rupture. Nonetheless, its relation to the incidence of ACL reconstruction and revision failure is not well established and requires further research.

Although this study is a controlled prospective analysis with a relatively suitable patient population size, few limitations are present. Differences in sex between both groups were not investigated in the present study. We did not perform either the interobserver or intraobserver reliability tests. We did not use MRI for measurement. Moreover, knee laxity measurements were not performed in the present study. Finally, the relation between the depth of the distal femoral condyles and the incidence of ACL reconstruction and revision failure was not studied. So, further investigations and research are needed to further determine the distal femur morphology in the Egyptian population and its effect on the risk of primary and secondary ACL injury.

## Conclusions

The data from our study demonstrated that an increase in posterior femoral condyle ratio was associated with an increased prevalence of ACL injuries in Egyptian population. However, further research is needed to determine the distal femur morphology in the Egyptian population and its effect on the risk of primary and secondary ACL injury.

## Financial support and sponsorship

Nil.

## Conflicts of interest

There are no conflicts of interest.

## References

- Vasta S, Andrade R, Pereira R, Bastos R, Battaglia AG, Papalia R, Espregueira-Mendes J. Bone morphology and morphometry of the lateral femoral condyle is a risk factor for ACL injury. *Knee Surg Sports Traumatol Arthrosc* 2018; 26:2817–2825.
- Gianotti SM, Marshall SW, Hume PA, Bunt L. Incidence of anterior cruciate ligament injury and other knee ligament injuries: a national population-based study. *J Sci Med Sport* 2009; 12:622–627.
- Lohmander LS, Ostenberg A, Englund M, Roos H. High prevalence of knee osteoarthritis, pain, and functional limitations in female soccer players twelve years after anterior cruciate ligament injury. *Arthritis Rheum* 2004; 50:3145–3152.
- Voleti PB. A novel anatomic risk factor for anterior cruciate ligament injury? Commentary on an article by Thomas R. Pfeiffer, MD, et al.: 'an increased lateral femoral condyle ratio is a risk factor for anterior cruciate ligament injury'. *J Bone Joint Surg Am* 2018; 100:e74.

- 5 Alentorn-Geli E, Myer GD, Silvers HJ, Samitier G, Romero D, Lazaro-Haro C, *et al.* Prevention of non-contact anterior cruciate ligament injuries in soccer players. Part 1: mechanisms of injury and underlying risk factors. *Knee Surg Sports Traumatol Arthrosc* 2009; 17:705–729.
- 6 Hewett TE, Myer GD, Ford KR. Anterior cruciate ligament injuries in female athletes part 1, mechanisms and risk factors. *Am J Sports Med* 2006; 34:299–311.
- 7 Griffin LY, Albohm MJ, Arendt EA, Bahr R, Beynnon BD, Demaio M, *et al.* Understanding and preventing noncontact anterior cruciate ligament injuries: a review of the Hunt Valley II meeting, January 2005. *Am J Sports Med* 2006; 34:1512–1532.
- 8 Pfeiffer TR, Burnham JM, Kanakamedala AC, Hughes JD, Irrgang JJ, Debski R, Musahl V. A cam shaped femur might be a risk factor for ACL injuries. *Orthop J Sports Med* 2018; 6(Suppl 4):2325967118S00139.
- 9 Guzzini M, Mazza D, Fabbri M, Lanzetti R, Redler A, Iorio C, *et al.* Extra-articular tenodesis combined with an anterior cruciate ligament reconstruction in acute anterior cruciate ligament tear in elite female football players. *Int Orthop* 2016; 40:2091–2096.
- 10 Hofbauer M, Thorhauer ED, Abebe E, Bey M, Tashman S. Altered tibiofemoral kinematics in the affected knee and compensatory changes in the contralateral knee after anterior cruciate ligament reconstruction. *Am J Sports Med* 2014; 42:2715–2721.
- 11 Hart HF, Culvenor AG, Collins NJ, Ackland DC, Cowan SM, Machotka Z, *et al.* Knee kinematics and joint moments during gait following anterior cruciate ligament reconstruction: a systematic review and meta-analysis. *Br J Sports Med* 2016; 50:597–612.
- 12 Titchenal MR, Chu CR, Erhart-Hledik JC, Andriacchi TP. Early changes in knee center of rotation during walking after anterior cruciate ligament reconstruction correlate with later changes in patient-reported outcomes. *Am J Sports Med* 2017; 45:915–921.
- 13 Williams A, Ball S, Stephen J, White N, Jones M, Amis A. The scientific rationale for lateral tenodesis augmentation of intra-articular ACL reconstruction using a modified 'Lemaire' procedure. *Knee Surg Sports Traumatol Arthrosc* 2017; 25:1339–1344.
- 14 Dejour D, Saffarini M, Demey G, Baverel L. Tibial slope correction combined with second revision ACL produces good knee stability and prevents graft rupture. *Knee Surg Sports Traumatol Arthrosc* 2015; 23:2846–2852.
- 15 Sonnery-Cottet B, Mogos S, Thaanat M, Archbold P, Fayard JM, Freychet B, *et al.* Proximal tibial anterior closing wedge osteotomy in repeat revision of anterior cruciate ligament reconstruction. *Am J Sports Med* 2014; 42:1873–1880.
- 16 Voleti PB, Stephenson JW, Lotke PA, Lee GC. Plain radiographs underestimate the asymmetry of the posterior condylar offset of the knee compared with MRI. *Clin Orthop Relat Res* 2014; 472:155–161.
- 17 Wernicke GC, Seeto BG, Chen DB, MacDessi SJ. Posterior condylar cartilage thickness and posterior condylar offset of the femur: a magnetic resonance imaging study. *J Orthop Surg (Hong Kong)* 2016; 24:12–15.

#### Author Queries???

AQ1: A running head short title was not supplied; please check if this one is suitable and, if not, please supply a short title of up to 40 characters that can be used instead.

AQ2: Please confirm whether Original article given as dothead is correct.

AQ3: Please provide postal/zip code, tel (office), and fax numbers for the corresponding author.

AQ4: Please provide date of submission/acceptance.